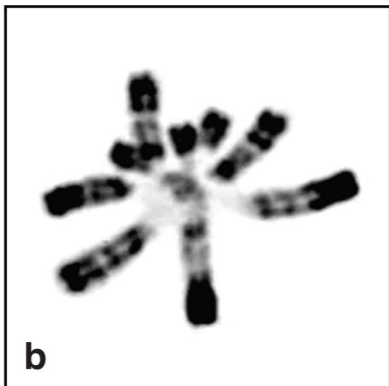




a



b

Figure 5. Genetic Disorders Affecting Chromatin in *cis*

(a) This photo of a Rett syndrome patient illustrates the unusual stereotyped hand movements, teeth grinding, and abnormal posture. Photo kindly provided by Dr. Daniel G. Glaze. (b) Micrograph of chromosomes from an ICF patient, courtesy of Drs. Timothy H. Bestor, Robert A. Rollins, and Deborah Bourc'his.